



Botulinum toxin in the management of facial paralysis

Jonathan A. Cabin^a, Guy G. Massry^{b,c,d}, and Babak Azizzadeh^{e,f}

Purpose of review

Complete flaccid facial paralysis, as well as the synkinetic and hyperkinetic sequelae of partial recovery, has significant impact on quality of life. Patients suffer from functional deficiencies, cosmetic deformity, discomfort and social consequences leading to emotional distress. Despite an extensive and sophisticated array of available interventions for facial reanimation, most patients have persistent issues that require consistent follow-up. In long-term management, botulinum toxin (BT) injection remains a critical tool in the treatment of the facial paralysis patient, particularly in the case of synkinesis, hyperkinesis and imbalance. We review the recent scientific literature and highlight key principles and developments in the use of BT in the management of facial paralysis, including less common applications for acute facial paralysis, hyperlacrimation and pseudoptosis.

Recent findings

We reviewed the literature for the latest advances in the use of BT in facial paralysis, including applications and technique, as well as measurement tools and adjunct exercises. We also share our experience in treating our own patient population.

Summary

BT continues to be a well tolerated and effective tool in the long-term management of facial paralysis, specifically in treating synkinesis, imbalance and hyperkinesis, as well as hyperlacrimation and pseudoptosis. Consistent measurement tools and adjunct neuromuscular retraining are crucial in the successful deployment of BT. Controversy exists as to whether BT should be used to manage facial paralysis during the acute phase, and whether BT application to the nonparalyzed face can improve long-term recovery in the paralyzed side.

Keywords

Bell's palsy, botulinum toxin, facial paralysis, hyperkinesis, synkinesis

INTRODUCTION

Facial paralysis with resultant permanent paresis and synkinesis presents tremendous management issues for the practitioner. Even in the case of Bell's palsy, which has a favorable prognosis, up to 30% of patients will have incomplete functional or aesthetic recovery [1–3].

Botulinum toxin (BT) chemically denervates muscle by irreversibly blocking presynaptic acetylcholine release. After direct muscular injection, BT maintains effect until newly sprouted axon terminals regain synaptic contact with the muscle, typically occurring between 3 and 6 months posttreatment [2,4–6]. Since its first reported use in 1973 for the treatment of strabismus, BT has been successfully applied to a multitude of muscular disorders [4,5,7–11]. The use of BT for the treatment of synkinesis was first reported in the German literature in 1991, in the elimination of

involuntary oro-ocular eye closure [12,13]. In recent years, BT has been increasingly employed in cases of facial imbalance, hyperkinesis and synkinesis in the setting of previous facial nerve injury [1,14–22]. Recent research has demonstrated the value of

^aDepartment of Otolaryngology-Head and Neck Surgery, New York Eye and Ear Infirmary of Mount Sinai, New York, New York, ^bOphthalmic Plastic and Reconstructive Surgery, Keck School of Medicine, University of Southern California, Los Angeles, ^cBeverly Hills Ophthalmic Plastic and Reconstructive Surgery, ^dThe Facial Paralysis Institute, Beverly Hills, ^eDepartment of Head and Neck Surgery, David Geffen School of Medicine at UCLA, Los Angeles and ^fCenter for Advanced Facial Plastic Surgery, Beverly Hills, California, USA

Correspondence to Babak Azizzadeh, Center for Advanced Facial Plastic Surgery, 9401 Wilshire Blvd #650, Beverly Hills, CA 90212, USA. Tel: +1 310 657 2203; e-mail: MD@FacialPlastics.info

Curr Opin Otolaryngol Head Neck Surg 2015, 23:000–000

DOI:10.1097/MOO.0000000000000176

Facial plastic surgery

KEY POINTS

- The lasting sequelae of partial facial paralysis can have a profound impact on patient quality of life.
- Botulinum toxin injection is a well tolerated and effective treatment for synkinesis, hyperkinesis and facial imbalance.
- Botulinum toxin can be effective in rarer sequelae of facial paralysis, including psuedoptosis and hyperlacrimation.
- Preliminary research suggests that botulinum toxin may be used in the acute phase of facial paralysis, and that nonparalyzed side botulinum toxin injections may improve the long-term recovery of the paralyzed side.
- Careful measurement, documentation and routine follow-up is key in the use of botulinum toxin in the treatment of facial paralysis.
- Patients should be offered neuromuscular feedback physical therapy, as these exercises are synergistic with botulinum toxin injections in improving synkinesis, hyperkinesis and imbalance.

concomitant neuromuscular retraining and physical therapy, which can enhance the effectiveness of BT and lead to a more favorable and lasting result [23–26].

Two commercial forms of BT, type A (BTX-A) and type B (BTX-B), are currently available, identical in action but differing in potency. BTX-A and BTX-B are also thought to also vary slightly in onset, duration and diffusion [4,27]. BTX-A and BTX-B are produced by different strains of *Clostridium botulinum*, with BTX-A being the most powerful and common form used clinically [1,28]. Other *C. botulinum* strains include C, D, E, F and G, none of which has yet been used to commercially produce BT [4,29,30]. The most universally available forms of BT are onabotulinumtoxinA (ONA; Botox Cosmetic and Vistabel, Allergan, Inc., Irvine, California) and abobotulinumtoxinA (ABO; Dysport, Medicis Aesthetics, Inc., Scottsdale, Arizona; Azza-lure, Galderma Laboratories, Lausanne, Switzerland), both types of BTX-A with differing manufacturing processes, resulting in different concentrations and nontoxic proteins. BTX-B is available as rimabotulinumtoxinB (Myobloc, Solstice Neurosciences, LLC, Louisville, Kentucky) but is yet to be well established in the treatment of facial muscular disorders, and is only FDA approved for cervical dystonia [4,31,32,33^{*}]. Theoretically all forms of BT can be used similarly in treatment, keeping in mind the differences in potency [12,34]. There are reports of decreased efficacy

and increased tolerance of BTX-A, with response to BTX-B in these cases [14,16,35]. Given the general lifelong need for BT in facial paralysis, as well as the ever-increasing number of patients receiving this treatment, BTX-A tolerance could eventually be seen more frequently in this population.

For consistency, we refer to the ONA form of BTX-A (hereafter referred to as BT).

TEXT OF REVIEW

Facial musculature

In considering the application of BT to a patient suffering from acute or chronic facial paralysis, it is important to have an understanding of the facial musculature and its role in aesthetics and function (Fig. 1). As discussed below, depending on the individual patient dysfunction, various combinations of these muscles will require BT injection.

Synkinesis and hyperkinesis

Flaccid paralysis versus synkinesis

Individuals who suffer irreversible and complete facial nerve paralysis have very different functional and aesthetic outcome than those who have regeneration of the facial nerve or undergo cranial nerve substitution techniques such as hypoglossal–facial nerve transfer. Flaccid paralysis results in significant functional deficits such as oral incompetence, poor articulation, lip and buccal mucosa biting, as well as lagophthalmos with potential for corneal ulceration and blindness. Furthermore, these individuals develop an effaced nasolabial fold, severe facial atrophy, brow and facial ptosis and absent animation, most importantly smile mechanism, on the affected side.

Patients who undergo cranial nerve substitution techniques, direct or cable nerve grafting, or have reversible facial nerve palsy such as Bell's palsy may develop synkinesis. Synkinesis is defined as the involuntary movement of one mimetic muscle group with the voluntary movement of a second muscle group. Classically, synkinesis is thought to arise from the aberrant regeneration of facial nerve fibers, but has also been theorized to result from ineffective myelination (leading to nerve cross-talk), or a centralized, postinjury hypersensitization of the facial nucleus [23,36^{*}]. Synkinesis occurs in up to 10% of patients after recovery from Bell's palsy [27,37].

Synkinesis can also result in functional deficits similar to flaccid paralysis; the visible facial deformities, however, are quite different than in cases of

complete paralysis. Patients typically have resting and dynamic facial asymmetry; hyperactivity of facial muscles; eyelid aperture narrowing; poor oral commissure excursion and smile mechanism; hyperlacrimation; deepening of the nasolabial fold; a prominent platysma and eyebrow elevation. Although the mechanism of action for smile dysfunction with synkinesis is controversial, the hyperkinetic activity of the platysma, buccinators and depressor anguli oris is likely a contributing factor to the limitation in oral commissure excursion.

Synkinetic movements are traditionally labeled with a composite term, whereby the muscle group of intended movement is followed by the muscle group of unintended movement; i.e., 'oculo-oral' involves the involuntary movement of the oral commissure with voluntary eye closure. Although synkinesis is best thought of as on a spectrum, oculo-oral and oro-ocular remain the most common general forms of synkinesis, with several specific subcategories within these classes [20,28]. In particular, Marin-Amat's syndrome (eye closure upon jaw opening or lateral jaw movement) and pseudoptosis (ptosis without malfunction of the levator palpebrae superioris or Mueller's muscle) are two of the more commonly reported subtypes of oro-ocular synkinesis [29,30,38]. Synkinetic firing of the platysma is also frequently encountered with facial movements of eye closure and/or smile, resulting in cosmetic, functional and sometimes painful contraction [24–26,31,32,33,39–43].

Gustatory hyperlacrimation, or crocodile tear syndrome (CTS), which involves unintentional unilateral lacrimation with food consumption, is also thought to be a synkinetic sequelae of facial paralysis. It is suspected that CTS results from the misdirection of regenerating gustatory fibers through the greater petrosal nerve [34,44,45,46].

Given the general heterogeneity of synkinetic movement, standardized measurement has always been controversial and challenging, with intraobserver reliability varying considerably. Although the House–Brackmann scale is the most widely utilized grading system in facial paresis and paralysis, other scales, such as the Sunnybrook Facial Grading System, are also well studied but more comprehensively addressed synkinesis [35,47]. The Sunnybrook Facial Grading System has also specifically been used to evaluate the effectiveness of BT in the treatment of synkinesis [20,36,47]. Standardized patient-reported surveys have also been simultaneously employed alongside observer scales to study synkinesis [17,37]. To guide individualized treatment, we recommend that

practitioners maintain a grading system for synkinesis throughout the care continuum.

Hyperkinesis and facial imbalance

The nonparalyzed side can also be targeted to create symmetry with the paralyzed or paretic side. Although the term 'synkinesis' is used to describe involuntary movement of one mimetic muscle group with the voluntary movement of a second muscle group on the affected side, 'hyperkinesis' is broadly used to define the asymmetric static and dynamic hyperactivity of the normal side. As a result, selective neuromodulation of specific facial muscles on the unaffected side can help create more resting and dynamic symmetry in patients with complete paralysis or synkinesis. Although not observed in the senior author's (B.A.) practice, it has also been suggested that BT application on the unaffected side can positively affect the long-term recovery and function of the paralyzed side [20,48].

Technique

In addressing the patient with incomplete recovery from facial paralysis, it is crucial to take a global view of the disorder. In total paralysis without reinnervation, BT is only useful on the nonparalyzed face to balance movement and treat hyperkinesis; however, in most cases of partial recovery, patients suffering from long-term sequelae of facial paralysis are best served by concomitant treatment of synkinesis on the affected side, and compensatory hyperkinesis on the unaffected side.

Timing

Except in cases of confirmed facial nerve transection without surgical reinnervation, most recommend applying BT treatment on the affected side only after the majority of reinnervation is achieved. The underlying rationale is to avoid overtreatment, and to prevent the introduction of confounding factors into tracking the natural course of recovery. In the case of Bell's palsy, recovery is thought to occur within 4–6 months [17,34,38,49–51]. For those with surgical treatment, recovery has been observed up to a year postoperatively. Although patients can get worsening hyperkinesis after full potential of recovery is achieved, early normal-side BT balancing injections can be utilized.

BT takes effect within 12–18 h, lasting 3–6 months and with maximal effect 4–7 days after injection. Most will notice decreasing efficacy at

Facial plastic surgery

approximately 1 month. It typically takes several sessions to develop an individualized dosing regimen.

Pretreatment

Prior to BT injection, a full history should be obtained, with particular attention to the time course of the disorder, as well as any contraindica-

targeted BT injection into this muscle area. Dosing and injection location are specific to each patient. A deep knowledge of facial musculature anatomy, along with careful evaluation of individual facial movement, is key to determining required injection areas.

The typical regions on the affected side include the following: orbicularis oculi to reduce narrowing of eyelid aperture; platysma to reduce banding and

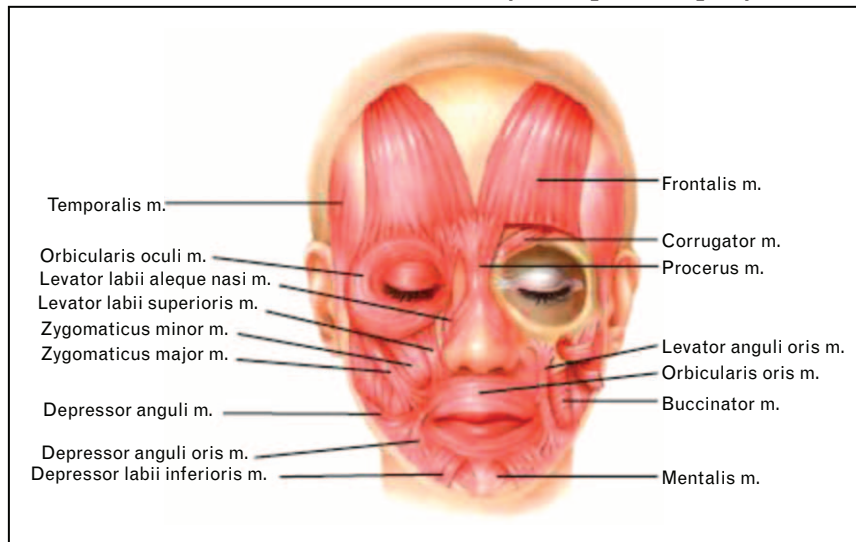


FIGURE 1. The muscles of facial expression. Source: Figures 2–19 in *Master Techniques in Facial Rejuvenation*, Azzadeh/Murphy/Johnson/Massry, 2006, Elsevier.

tions to BT use (pregnancy, lactation, myasthenia gravis, peripheral motor neuropathies, active infections or previous adverse reaction). Photographic and/or videographic documentation, facial analysis and grading should be performed, and an injection plan should subsequently be developed. Counseling should be provided regarding the injection process, timeline of effectiveness, side-effects and potential risks, particularly when treating new patients. A consent form should be obtained at each visit.

The intended areas of injection can be pretreated. In our practice, we do not use any anesthesia, and apply only an alcohol wipe before injection. Some practices utilize ice compresses to promote vascular constriction and anesthesia and/or lidocaine/prilocaine cream (EMLA; Astra Zeneca, Milan, Italy).

We dilute 100 units of Botox in 4.0 ml of 0.9% saline for a concentration of 2.5 U in 0.1 ml and use a 1 ml syringe with a 32-gauge needle for delivery.

Dosing

In the case of synkinesis, the goal of BT treatment is to reduce or eliminate the involuntary muscle action that is aberrantly triggered, achieved by

tightness in the neck; buccinator; mentalis to reduce chin dimpling and occasionally the frontalis and corrugator supercilli to reduce tension and relax the forehead. The platysma, buccinators and depressor anguli oris need to be aggressively injected to improve the smile mechanism albeit usually with limited success.

The unaffected side is also injected to create balance, improve hyperkinesis and create more symmetry at rest and with animation in patients with complete paralysis or synkinesis. The following areas are usually considered: levator labii alaeque nasi to reduce the visibility of the upper teeth; depressor labii inferioris to reduce the visibility of the lower teeth and orbicularis oculi and frontalis to match the contralateral rhytids (Fig. 2). The dosing ranges and areas of injection are outlined in Table 1.

Titration is necessary to minimize the effect on intended function while maximizing treatment of unintended motion. We recommend injecting lower-than-normal amounts at the initial treatment session, with a 2-week follow-up for possible additional injections. This allows for careful titration and precise understanding of the patient's BT requirements. After several sessions, a customized dosing regimen should develop.



FIGURE 2. Botulinum toxin injections. Sequence of movements: face neutral, small smile, big smile/grin, raised eyebrows, furrowed eyebrows, mouth puckered/whistling, lower lip down/showing bottom teeth, upper lip up/showing top teeth/snarling. Source: Babak Azizzadeh, MD. (a) Heading: 43-year-old female before and 7 weeks after BT injection for synkinesis and balancing. (b) Heading: 47-year-old female before and 4 weeks after BT injection for synkinesis and balancing (also includes Restylene injection to bilateral infraorbital areas and nonparalyzed [left] nasolabial fold). (c) Heading: 48-year-old female before and 2 weeks after BT injection for synkinesis and balancing.

Concomitant exercises (i.e. mirror feedback)

Physical therapy in the form of neuromuscular retraining has been well documented in the treatment of synkinesis [24–26,34,39–43]. Several studies have also demonstrated the synergistic effect of physical rehabilitation combined with BT injection

in the synkinetic and asymmetric facial paralysis patient. In particular, initiation of neuromuscular retraining and mirror biofeedback after BT injection has been shown to enhance the effects of BT injection, with persistent improvement in synkinesis and imbalance after the pharmacologic effects of BT have long dissipated [17,44,45,46²⁴,50].

Facial plastic surgery



FIGURE 2. (Continued)

OTHER USES

Acute facial paralysis

Depending on the type of injury suffered, facial nerve paralysis or paresis is likely to fully resolve without any long-term sequelae. The acute postinjury period, usually defined as 3 months, has recently been discussed as a potential treatment window for BT application, particularly in patients who do not qualify for medical or surgical

intervention [34,47,51]. Some studies have shown that weakening the unaffected side contributes to strengthening and improved functionality of the affected side; in this context, it has been suggested but not proven that acute-phase BT injections could play a positive role in long-term recovery [20,34,47,51]. Although we rarely employ BT in our own practice during the acute phase of facial paralysis, this is a topic of ongoing discussion and controversy. Technique and dosing for normal side BT injection in the acute phase and chronic phase are identical, with emphasis on titration and patient education.

Table 1. Botulinum toxin dosing ranges for synkinesis

Muscle	Dose range (units of BT)
Affected side	
Corrugator Supercilii	5–10
Orbicularis Oculi	2.5–7.5
Buccinators	10–20
Depressor Anguli Oris	2.5–10
Mentalis	2.5–10
Platysma	10–30
Unaffected side	
Frontalis	5–10
Orbicularis Oculi	7.5–10
Levator Labii Alaeque Nasi	2.5–7.5
Depressor Labii Inferioris	2.5–5

Hyperlacrimation

A rare complaint in facial paralysis patients is the development of lacrimation with taste stimulation (CTS), likely caused by rerouting of the facial nerve's visceromotor fibers to the lacrimal gland [17,34]. After injury these autonomic facial nerve fibers may redirect, through the greater superficial petrosal nerve, to the lacrimal gland. Another explanation is that rather than nerve regeneration/reinnervation, an abnormal synapse occurs at the site of injury causing crossover of impulse from one fiber to another (afferent/efferent) [17,34,48–51]. In both instances, this aberrant neurophenomenon results in ipsilateral tearing when the patient eats. As the

lacrimal gland is affected by cholinergic neurons of the parasympathetic nervous system, several small case series have reported the success of controlling hyperlacrimation with BT injection directly into this gland [17,34,49–51]. The duration of effect has been shown to last up to 6 months [52], potentially requiring less frequency of BT injection as compared with other areas of BT treatment in facial paralysis.

It is imperative that prior to treatment, CTS is confirmed and dry eye is ruled out. Confirmation can be achieved by application of Schirmer's test twice, with and without simultaneous sweet–sour taste stimulation. A full eye examination should also be performed [34,53].

There is controversy as to the BT injection technique for CTS and, as this is a relatively rare condition, consensus is absent. Some authors prefer a transcutaneous injection without direct visualization of the gland [17,30,50], whereas others describe a transconjunctival approach with direct gland visualization [17,19,34,51,54]. In the author's practice (G.G.M.), transconjunctival injections are preferred, as we find that less BT is required for successful treatment. Review of the literature demonstrates a similar preference, due not only to the decreased BT requirements, but also to lower ptosis risk. These differences are likely because of a more direct injection of the gland with the transconjunctival method [30,34,51].

For transcutaneous injection, patients are asked to look infero-medially with injection at the inferior portion of the junction of the middle and lateral third of the superior orbital rim. For transconjunctival injection, after topical anesthesia is applied to the eye, the upper lid is everted whereas pressure is applied at the lateral canthus to expose the palpebral lobe of the lacrimal gland [30,34]. Ten to 20 units of BT are typically injected, always starting with a lower dose in new patients, with subsequent upward titration as needed [16,17,34,49–51].

Before injection, patients should be counseled regarding the significant discomfort with injection, as well as subsequent potential for dry eye syndrome. The major risk of lacrimal gland injection is lid ptosis, related to the proximity of the levator palpebrae superioris muscle [34,55]. As with all incidents of post-BT ptosis, treatment with alpraxolone 0.5%, or other alpha-adrenergic agonist eye drops, can ameliorate this complication [53,56].

Pseudoptosis

Pseudoptosis is a relatively rare consequence of facial paralysis, and refers to the appearance of blepharoptosis with normal levator palpebrae

superioris functioning. It is thought to be of synkinetic origin, whereby involuntary palpebral orbicularis oculi contracture results from voluntary orbicularis oris action (oro-ocular). Pseudoptosis can result in cosmetic imbalance, unintended social cues and visual obstruction [30,31].

BT injection to the palpebral portion of the orbicularis oculi can treat pseudoptosis; however, the literature describes a significant side-effect profile, including worsening blepharoptosis, lagophthalmos and diplopia [16,17,19,54]. None of these studies, however, specifically addresses pseudoptosis and more generally discusses the treatment of oro-ocular synkinesis; as such, the attribution of side-effects is hard to parse out. In a study by McElhinny *et al.* pseudoptosis is addressed specifically, with targeted injections to the upper palpebral orbicularis oculi only. It was demonstrated that a high success and low complication rate is achievable by injecting small amounts of BT (5–15 units) into the pretarsal, upper eyelid orbicularis oculi, in two to three locations [28,30].

Before injection, measurement of margin reflex distance should be performed while asking the patient to contract the orbicularis oris through the pursing of lips. Using the margin reflex distance, as well as subjective patient feedback, effective injection amounts can be developed and utilized over time [30,31,57,58].

Alternative treatments

Given its effectiveness, ease of use and minimal invasiveness, BT has become the standard of care in synkinesis and hyperkinesis treatment; however, selective neurectomy is the most utilized alternative when BT injections have become ineffective or are poorly tolerated, or in cases in which a more lasting solution is preferred [16,57]. This procedure involves transection of facial nerve branches observed to be contributing to synkinetic mis-firing or muscle overaction. First described in 1950 by Marino and Alurralde [55,58], it was later modified by Dobie and Fisch in 1986 to include extirpation and ablation of contributory branches under general anesthesia [31,56,59,60]. It has since been described as an excellent option for synkinetic and hyperkinetic movement of the platysma [31,60], and most recently as an alternative to BT for oro-ocular synkinesis. In the study by Hohman *et al.* facial nerve branches were extirpated under general anesthesia, with selective ablation of the offending branch(es) once the patient is awake and able to replicate aberrant movement [16,61]. Although initially effective, recurrence of the muscular disorder, occasionally in a more severe form, has been anecdotally reported [28,62].

Facial plastic surgery

Selective myectomy or myotomy has also been utilized in treatment of synkinesis and hyperkinesis, variously reported for periorbital, periocular and platysmal treatment in both the affected and unaffected sides [14,31,57,58]. The procedure involves isolation and transection of the problematic muscle, frequently in combination with other therapies such as grafting, neurectomy and BT. Several approaches have been developed, including direct treatment of hyperkinetic nasalis [16,57], ablation of perioral muscles in patients with oro-ocular synkinesis [30,58] and the ablation of involuntary synkinetic platysma or levator on the affected side [31,53,59,60]. Although generally unpredictable over the long term, platysmectomy has been reported successful in suppressing unwanted platysmal contraction and may be a suitable alternative to BT [60,63].

In our practice, we are currently looking into the effectiveness of selective neurectomy and myotomy as an alternative for BT injections to platysma and buccinators muscles.

Cryotherapy and radiofrequency are well described in their cosmetic application to skin and muscle [30,34,61], and time will tell whether these treatments can be applied to postparalytic sequelae currently treated with BT.

Pitfalls

In addition to the more common risks of BT injection, such as bruising and edema, BT injection for facial paralysis is slightly higher risk than typical cosmetic or targeted uses, given the higher cumulative dosage, riskier areas of injection and need for long-term, repeated use. Before initiation of treatment, patients should be counseled as to the potential side-effects and complications of BT injections.

There is controversy in the literature regarding the diminishing effectiveness of BT due to the development of antibodies [53,62,64]. Loss of BTX-A effectiveness could necessitate transition to different BT strains (e.g. BTX-B) in patients who no longer satisfactorily respond to BTX-A [14,53], or eventually require other more invasive forms of targeted muscle suppression (discussed above) [5,16]. In our practice, facial paralysis patients typically receive BTX-A injections every 3–4 months, and we have observed only rare occasions of increased tolerance. In these cases, titration of dosing has restored adequate effectiveness.

BT overtreatment is a potential issue, given the large quantity of BT typically required in facial paralysis patients. Although overtreatment can cause cosmetic and expressional deficiencies, such

as smile dysfunction or brow ptosis, the most worrisome complication is the elimination of function, causing oral incompetence, speech abnormalities and lagophthalmos.

Oral incompetence and/or speech abnormalities are rare complications resulting from overinjection of the oral musculature (typically depressor anguli oris, depressor labii inferioris or levator labii alaeque nasi), or misinjection of the orbicularis oris. In our experience, overinjection of targeted oral musculature can cause transient speech difficulty and, rarely, oral incompetence. These issues tend to subside as patients quickly adapt to a new muscular equilibrium. We have never encountered a patient with long-term oral incompetence from orbicularis oris injection. The incidence of overtreatment can be minimized by carefully titrating up from lower doses when injecting new patients.

Lagophthalmos is a relatively common side-effect of BT treatment for pseudoptosis, as injection directly targets the palpebral portion of the orbicularis muscle (as discussed above) [30]. More rarely, lagophthalmos can result from overinjection and/or spread of injection from the orbicularis oculi, in attempting to treat aperture narrowing. As in any case of lagophthalmos, treatment should focus on corneal protection with aggressive eye lubrication and taping with sleep, until the orbicularis oculi suppression diminishes and full closure is once again achieved. Again, careful BT dose titration, especially in cases of pseudoptosis, can minimize the incidence of lagophthalmos.

Blepharoptosis is a relatively frequent complication of BT injection to the upper-third of the face, resulting in temporary cosmetic and visual disturbances. Caused by unintentional BT diffusion to the levator palpebrae superioris muscle, it is also hypothesized to occur after injection of the frontalis 'unmasks' a hidden ptosis, which had previously been counterbalanced by subtle frontalis action [53]. A recent meta-analysis demonstrated a dose-dependent 2.5% overall incidence of blepharoptosis with cosmetic injection, with up to 21% dose-dependent incidence with diffuse upper face injection [63]. Blepharoptosis is particularly common in the treatment of eye specific facial paralysis sequelae, given the significant proximity of the levator palpebrae superioris to required injections [30,34]. Blepharoptosis manifests between 48 h to 1 week following treatment, and typically resolves within 2–6 weeks [53,64]. It can be treated with titrated alpha-adrenergic agonist eye drops, such as apraclonidine 0.5%, stimulating Mueller's muscle to elevate the lid [53].

Cases of systemic weakness and toxicity have been described with BT, although this rare

complication has been limited to patients receiving large doses of BT for treatment of nonfacial muscle disorders (i.e. cerebral palsy and poststroke spasm) [5], or in those treated with unapproved BT in exponentially larger concentrations than intended [2,3,13]. Although never reported in facial injection of approved pharmacologic BT, given both the larger-than-typical doses of BT and the routine treatment of children, practitioners using BT for facial paralysis should be familiar with the signs and symptoms of BT toxicity. Symptoms include generalized limb weakness, fatigue and dysphasia, with florid botulism, paralysis and respiratory arrest only reported in cases of injection of unapproved BT formulation in unintentionally high concentrations [1,2,5,6,15,17–22]. Although controversy exists as to the method of absorption, as well as the existence of cumulative or weight-based toxicity of BT, case reports have demonstrated rare systemic symptoms in repeated local BT injections of as little as 7 units of BTX-A per kilogram or totals of 600 units per session, but with doses of over 30 units per kilogram or totals of over 1200 units per session safely and repeatedly given [5,7–11,24–26]. Although prudent to keep in mind total dosage, especially in young children, total BT dosing should remain well under any level of concern in the course of treating facial paralysis patients.

CONCLUSION

BT injection has become indispensable in treating facial paralysis and its long-term sequelae. With general synkinesis, facial imbalance and hyperkinesis, the careful and targeted application of BT injections is well tolerated and effective. BT can also be successfully applied in the treatment of the more uncommon sequelae of hyperlacrimation and pseudoptosis. When using BT, the practitioner should be well versed in the subtleties of facial musculature and the potential pitfalls of injection. In our practice, we employ neuromuscular retraining and BT injection and believe that they can have synergistic activity in improving the symptoms of facial palsy. Future research will dictate whether selective neurectomy, myectomy, cryotherapy or radiofrequency can provide similar success in treatment, with longer-term or permanent improvements.

Acknowledgements

None.

Financial support and sponsorship

None.

Conflicts of interest

There are no conflicts of interest.

AQ2

REFERENCES AND RECOMMENDED READING

Papers of particular interest, published within the annual period of review, have been highlighted as:

- of special interest
- of outstanding interest

1. Filipo R, Spahiu I, Covelli E, *et al.* Botulinum toxin in the treatment of facial synkinesis and hyperkinesis. *Laryngoscope* 2012; 122:266–270.
2. Souayah N, Karim H, Kamin SS, *et al.* Severe botulism after focal injection of botulinum toxin. *Neurology* 2006; 67:1855–1856.
3. Peitersen E. Bell's palsy: the spontaneous course of 2500 peripheral facial nerve palsies of different etiologies *Acta Otolaryngol Suppl* 2002; (549):4–30. AQ3
4. Yamauchi PS, Lowe NJ. Botulinum toxin types A and B: comparison of efficacy, duration, and dose-ranging studies for the treatment of facial rhytides and hyperhidrosis. *Clin Dermatol* 2004; 22:34–39.
5. Crowner BE, Torres-Russotto D, Carter AR, Racette BA. Systemic weakness after therapeutic injections of botulinum toxin a: a case series and review of the literature. *Clin Neuropharmacol* 2010; 33:243–247.
6. Pamphlett R. Early terminal and nodal sprouting of motor axons after botulinum toxin. *J Neurol Sci* 1989; 92:181–192.
7. Jankovic J, Brin MF. Therapeutic uses of botulinum toxin. *N Engl J Med* 1991; 324:1186–1194.
8. Varghese-Kroll E, Elovic EP. Contralateral weakness and fatigue after high-dose botulinum toxin injection for management of poststroke spasticity. *Am J Phys Med Rehabil* 2009; 88:495–499.
9. Goldstein EM. Safety of high-dose botulinum toxin type A therapy for the treatment of pediatric spasticity. *J Child Neurol* 2006; 21:189–192.
10. Willis AW, Crowner B, Brunstrom JE, *et al.* High dose botulinum toxin A for the treatment of lower extremity hypertonicity in children with cerebral palsy. *Dev Med Child Neurol* 2007; 49:818–822.
11. Howell K, Selber P, Graham HK, Reddihough D. Botulinum neurotoxin A: an unusual systemic effect. *J Paediatr Child Health* 2007; 43:499–501.
12. Kollewe K, Mohammadi B, Dengler R, Dressler D. Hemifacial spasm and reinnervation synkinesis: long-term treatment with either Botox® or Dysport®. *J Neural Transm* 2010; 117:759–763.
13. Roggenkämper P, Laskawi R, Damenz W, *et al.* Involuntary lid closure caused by defective healing of facial paralysis and its treatment with botulinum toxin. *Klin Monbl Augenheilkd* 1991; 198:268–270.
14. Alster TS, Lupton JR. Botulinum toxin type B for dynamic glabellar rhytides refractory to botulinum toxin type A. *Dermatol Surg* 2003; 29:516–518.
15. Choi KH, Rho SH, Lee JM, *et al.* Botulinum toxin injection of both sides of the face to treat postparalytic facial synkinesis. *Br J Plast Surg* 2013; 66:1058–1063.
16. Hohman MH, Lee LN, Hadlock TA. Two-step highly selective neurectomy for refractory periocular synkinesis. *Laryngoscope* 2013; 123:1385–1388.
17. Boroojerdi B, Ferbert A, Schwarz M, *et al.* Botulinum toxin treatment of synkinesis and hyperlacrimation after facial palsy. *J Neurol Neurosurg Psychiatr* 1998; 65:111–114.
18. Borodic G, Bartley M, Slattery W, *et al.* Botulinum toxin for aberrant facial nerve regeneration: double-blind, placebo-controlled trial using subjective endpoints. *Plast Reconstr Surg* 2005; 116:36–43.
19. Armstrong MW, Mountain RE, Murray JA. Treatment of facial synkinesis and facial asymmetry with botulinum toxin type A following facial nerve palsy. *Clin Otolaryngol Allied Sci* 1996; 21:15–20.
20. Salles AG, Toledo PN, Ferreira MC. Botulinum toxin injection in long-standing facial paralysis patients: improvement of facial symmetry observed up to 6 months. *Aesthetic Plast Surg* 2009; 33:582–590.
21. Mehta RP, Hadlock TA. Botulinum toxin and quality of life in patients with facial paralysis. *Arch Facial Plast Surg* 2008; 10:84–87.
22. de Maio MC, Bento RF. Botulinum toxin in facial palsy: an effective treatment for contralateral hyperkinesis. *Plast Reconstr Surg* 2007; 120:917–927.
23. Crumley RL. Mechanisms of synkinesis. *Laryngoscope* 1979; 89:1847–1854.
24. Diels HJ. Facial paralysis: is there a role for a therapist? *Facial Plast Surg* 2000; 16:361–364.
25. Diels HJ, Combs D. Neuromuscular retraining for facial paralysis. *Otolaryngol Clin NA* 1997; 30:727–743.
26. Diels HJ. Treatment of facial paralysis using electromyographic feedback: a case study. *Eur Arch Otorhinolaryngol* 1994; S129–S132.
27. Yamamoto E, Nishimura H, Hirono Y. Occurrence of sequelae in Bell's palsy. *Acta Otolaryngol Suppl* 1988; 446:93–96.
28. Husseman J, Mehta R. Management of synkinesis. *Facial Plast Surg* 2008; 24:242–249.

Facial plastic surgery

- 29.** Malhotra A. Marin-Amat syndrome: a case of acquired facial synkinesis. *BMJ Case Rep* 2013.
- 30.** McElhinny ER, Reich I, Burt B, *et al.* Treatment of pseudoptosis secondary to aberrant regeneration of the facial nerve with botulinum toxin type A. *Ophthalmic Plast Reconstr Surg* 2013; 29:175–178.
- 31.** Laskawi R, Rohrbach S, Rödel R. Surgical and nonsurgical treatment options in patients with movement disorders of the platysma. *J Oral Maxillofac Surg* 2002; 60:157–162.
- 32.** Moran CJ, Neely JG. Patterns of facial nerve synkinesis. *Laryngoscope* 1996; 106 (12 Pt 1):1491–1496.
- 33.** Dall'Angelo A, Mandrini S, Sala V, *et al.* Platysma synkinesis in facial palsy and botulinum toxin type A → *Laryngoscope* 2014.
- AQ4** **34.** Montoya FJ, Riddell CE, Caesar R, Hague S. Treatment of gustatory hyperlacrimation (crocodile tears) with injection of botulinum toxin into the lacrimal gland. *Eye (Lond)* 2002; 16:705–709.
- 35.** Coulson SE, Croxson GR, Adams RD, O'dwyer NJ. Reliability of the 'Sydney,' 'Sunnybrook,' and 'House Brackmann' facial grading systems to assess voluntary movement and synkinesis after facial nerve paralysis. *YMHN* 2005; 132:543–549.
- 36.** Couch SM, Chundury RV, Holds JB. Subjective and objective outcome measures in the treatment of facial nerve synkinesis with onabotulinumtoxin A (botox). *Ophthalm Plast Reconstr Surg* 2014; 30:246–250.
- 37.** Mehta RP, WernickRobinson M, Hadlock TA. Validation of the synkinesis assessment questionnaire. *Laryngoscope* 2007; 117:923–926.
- 38.** Holland NJ, Weiner GM. Recent developments in Bell's palsy. *BMJ* 2004; 329:553–557.
- 39.** Ross B, Nedzelski JM, McLean JA. Efficacy of feedback training in long-standing facial nerve paresis. *Laryngoscope* 1991; 101 (7 Pt 1):744–750.
- 40.** Segal B, Hunter T, Danys I, *et al.* Minimizing synkinesis during rehabilitation of the paralyzed face: preliminary assessment of a new small-movement therapy. *J Otolaryngol* 1995; 24:149–153.
- 41.** Brach JS, VanSwearingen JM, Lenert J, Johnson PC. Facial neuromuscular retraining for oral synkinesis. *Plast Reconstr Surg* 1997; 99:1922–1931.
- 42.** Nakamura K, Toda N, Sakamaki K, *et al.* Biofeedback rehabilitation for prevention of synkinesis after facial palsy. *YMHN* 2003; 128:539–543.
- 43.** Baricich A, Cabrio C, Paggio R, *et al.* Peripheral facial nerve palsy: how effective is rehabilitation? *Otol Neurotol* 2012; 33:1118–1126.
- 44.** Azuma T, Nakamura K, Takahashi M, *et al.* Mirror biofeedback rehabilitation after administration of single-dose botulinum toxin for treatment of facial synkinesis. *Otolaryngol Head Neck Surg* 2011; 146:40–45.
- 45.** Monini S, De Carlo A, Biagini M, *et al.* Combined protocol for treatment of secondary effects from facial nerve palsy. *Acta Otolaryngol* 2011; 131:882–886.
- 46.** Lee JM, Choi KH, Lim BW, *et al.* Half-mirror biofeedback exercise in combination with three botulinum toxin A injections for long-lasting treatment of facial sequelae after facial paralysis. *J Plast Reconstr Aesthet Surg* 2014.
- 47.** Kim J. Contralateral botulinum toxin injection to improve facial asymmetry after acute facial paralysis. *Otol Neurotol* 2013; 34:319–324.
- 48.** Sadjadpour K. Postfacial palsy phenomena: faulty nerve regeneration or ephaptic transmission? *Brain Res* 1975; 95:403–406.
- 49.** Keegan DJ, Geerling G, Lee JP, *et al.* Botulinum toxin treatment for hyperlacrimation secondary to aberrant regenerated seventh nerve palsy or salivary gland transplantation. *Br J Ophthalmol* 2002; 86:43–46.
- 50.** Hofmann RJ. Treatment of Frey's syndrome (gustatory sweating) and 'crocodile tears' (gustatory epiphora) with purified botulinum toxin. *Ophthalm Plast Reconstr Surg* 2000; 16:289–291.
- 51.** Riemann R, Pfennigsdorf S, Riemann E, Naumann M. Successful treatment of crocodile tears by injection of botulinum toxin into the lacrimal gland: a case report. *Ophthalmology* 1999; 106:2322–2324.
- 52.** Nava-Casta eda A, Tovilla-Canales JL, Boullousa V, *et al.* Duration of botulinum toxin effect in the treatment of crocodile tears. *Ophthalm Plast Reconstr Surg* 2006; 22:453–456.
- 53.** Vartanian AJ, Dayan SH. Complications of botulinum toxin A use in facial rejuvenation. *Facial Plast Surg Clin North Am* 2005; 13:1–10.
- 54.** Borodic GE, Pearce LB, Cheney M, *et al.* Botulinum A toxin for treatment of aberrant facial nerve regeneration. *Plast Reconstr Surg* 1993; 91:1042–1045.
- 55.** Marino H, Alurralde A. Spastic facial palsy; peripheral selective neurotomy. *Br J Plast Surg* 1950; 3:56–59.
- 56.** Dobie RA, Fisch U. Primary and revision surgery (selective neurectomy) for facial hyperkinesia. *Arch Otolaryngol Head Neck Surg* 1986; 112:154–163.
- 57.** Terzis JK, Karypidis D. Therapeutic strategies in postfacial paralysis synkinesis in adult patients. *Plast Reconstr Surg* 2012; 129:925e–939e.
- 58.** Guerrissi JO. Selective myectomy for postparetic facial synkinesis. *Plast Reconstr Surg* 1991; 87:459–466.
- 59.** Dillman DB, Anderson RL. Levator myectomy in synkinetic ptosis. *Arch Ophthalmol* 1984; 102:422–423.
- 60.** Henstrom DK, Malo JS, Cheney ML, Hadlock TA. Platysmectomy: an effective intervention for facial synkinesis and hypertonicity. *Arch Facial Plast Surg* 2011; 13:239–243.
- 61.** Mulholland RS. Nonexcisional, minimally invasive rejuvenation of the neck. *Clin Plast Surg* 2014; 41:11–31.
- 62.** Göschel H, Wohlfarth K, Frevert J, *et al.* Botulinum A toxin therapy: neutralizing and nonneutralizing antibodies – therapeutic consequences. *Exp Neurol* 1997; 147:96–102.
- 63.** Cavallini M, Cirillo P, Fundarò SP, *et al.* Safety of botulinum toxin A in aesthetic treatments: a systematic review of clinical studies. *Dermatol Surg* 2014; 40:525–536.
- 64.** Matarasso SL. Complications of botulinum A exotoxin for hyperfunctional lines. *Dermatol Surg* 1998; 24:1249–1254.

Dear Author,

During the preparation of your manuscript for typesetting, some queries have arisen. These are listed below. Please check your typeset proof carefully and mark any corrections in the margin as neatly as possible or compile them as a separate list. This form should then be returned with your marked proof/list of corrections to the Production Editor.

QUERIES: to be answered by AUTHOR/EDITOR

QUERY NO.	QUERY DETAILS	RESPONSE
<AQ1>	As per the style of the journal, the article should have a mention of the 'Conflicts of interest' in a separate section under Acknowledgement(s) section. This has been done. Please check and modify as necessary to 'There are no conflicts of interest' or an appropriate statement if required.	
<AQ2>	Please provide complete bibliographic details such as volume, year of publication, and page range for Refs. [3, 26, 29, 33, 46].	
<AQ3>	As per journal style, all annotated reference numbers must have bullets, and all reference numbers with bullets must have annotations. In the case of Refs. [33, 36, 46], please provide annotations.	
<AQ4>	Please check the presentation of the table for appropriateness.	